


CASE REPORT

Open Access



# Peripheral nervous system manifestations of Shiga toxin-producing *E. coli*-induced haemolytic uremic syndrome in children

Luisa Santangelo<sup>1†</sup>, Giuseppe Stefano Netti<sup>2\*†</sup> , Diletta Domenica Torres<sup>1</sup>, Giovanni Piscopo<sup>1</sup>, Vincenza Carbone<sup>1</sup>, Luciana Losito<sup>3</sup>, Leonardo Milella<sup>4</sup>, Maria Luigia Lasorella<sup>4</sup>, Pasquale Conti<sup>5</sup>, Delio Gagliardi<sup>5</sup>, Maria Chironna<sup>6</sup>, Federica Spadaccino<sup>2</sup>, Elena Bresin<sup>7</sup>, Antonio Trabacca<sup>3</sup>, Elena Ranieri<sup>2†</sup> and Mario Giordano<sup>1†</sup>

## Abstract

**Background:** The Neurological involvement is the most common extra-renal complication of Shiga toxin-producing *E. coli*-hemolytic uremic syndrome (HUS) or typical HUS. On brain magnetic resonance examination, main neurological signs encompass acute lesions of the basal ganglia and the white matter, which could usually regress after Eculizumab infusion. In contrast, peripheral nervous system (PNS) manifestations in typical HUS are very rare and, when occurring, they require a careful management of neurological sequelae and an intensive multidisciplinary neuro-rehabilitation program.

**Case presentation:** Here, we present two pediatric cases of severe and complicated typical HUS with PNS manifestations who required therapeutic treatment and an intensive multidisciplinary neuro-rehabilitation program. In both cases, PNS manifestations were followed by the recovery from typical HUS-related severe central neurological damage and manifested mainly with marked bilateral motor deficit and hyporeflexia/areflexia in the lower limbs. The peripheral polyneuropathy was treated with immunosuppressive therapy (methylprednisolone boluses, i.v. immunoglobulins, plasma exchange), followed by a prolonged intensive neuro-rehabilitation program. After 8 months of rehabilitation, both patients gained complete functional recovery.

**Conclusions:** PNS manifestations during typical HUS are a rare event and potentially leading to severe disability. A timely clinical assessment is mandatory to set up a prompt therapeutic and rehabilitation program and to obtain a complete clinical and functional recovery.

**Keywords:** Hemolytic uremic syndrome, Enterohemorrhagic *Escherichia Coli*, Peripheral nervous system, Eculizumab, Plasma exchange, Neurorehabilitation

\* Correspondence: [giuseppestefano.netti@unifg.it](mailto:giuseppestefano.netti@unifg.it)

<sup>†</sup>Luisa Santangelo and Giuseppe Stefano Netti contributed equally to this work.

<sup>†</sup>Elena Ranieri and Mario Giordano contributed equally as senior investigators.

<sup>2</sup>Department of Medical and Surgical Sciences, Clinical Pathology Unit and Center for Molecular Medicine, University of Foggia, Viale Luigi Pinto -, 71122 Foggia, Italy

Full list of author information is available at the end of the article



© The Author(s). 2021 **Open Access** This article is licensed under a Creative Commons Attribution 4.0 International License, which permits use, sharing, adaptation, distribution and reproduction in any medium or format, as long as you give appropriate credit to the original author(s) and the source, provide a link to the Creative Commons licence, and indicate if changes were made. The images or other third party material in this article are included in the article's Creative Commons licence, unless indicated otherwise in a credit line to the material. If material is not included in the article's Creative Commons licence and your intended use is not permitted by statutory regulation or exceeds the permitted use, you will need to obtain permission directly from the copyright holder. To view a copy of this licence, visit <http://creativecommons.org/licenses/by/4.0/>. The Creative Commons Public Domain Dedication waiver (<http://creativecommons.org/publicdomain/zero/1.0/>) applies to the data made available in this article, unless otherwise stated in a credit line to the data.

## Background

The hemolytic uremic syndrome (HUS) is a well-known but rare disease characterized by micro-angiopathic hemolytic anemia, thrombocytopenia, and organ damage, often renal dysfunction, which occurs both in adults and in children. The “typical” form (typical HUS) is mediated by Shiga-like toxin-producing *E. coli* (STEC) or, less commonly, by Shiga toxin-producing *S. dysenteriae* type 1 and *Streptococcus Pneumoniae* [1]. All other causes of HUS have traditionally been referred to as “atypical” (aHUS) in which main cases are due to dysregulation and over-activation of the alternative complement pathway [2–4], secondary to a gene mutation or, rarely, to acquired autoantibodies neutralizing some complement system components (e.g. anti-factor H antibodies) [5]. Rarely, clinical conditions, such as autoimmune diseases, transplantation, cancer, infectious diseases, pregnancy, or use of certain cytotoxic drugs, are associated with secondary forms of HUS [6]. In typical HUS, the Shiga-like toxin release follows the bloody diarrhea by *Enterohemorrhagic E. Coli*. The latter can cause systemic endothelial damage and thrombotic microangiopathy (TMA), which leads to the onset of the classic symptomatic triad (anemia, low platelet count and acute kidney injury). In severe forms of TMA with the involvement of the central nervous system (CNS), typical HUS-related morbidity and mortality significantly increase [7]. Neurologic complications are the most common extra-renal manifestations in typical HUS, accounting 20–25% of patients. Due to these severe forms, patients are at elevated risk of the worst outcome or serious long-term disability after the acute phase of the disease [8–11]. Peripheral nervous system (PNS) manifestations during typical HUS instead is very rare and limited cases are reported [12]. At now, the key role of the complement system dysregulation is well known in the atypical HUS, while rising evidence underlies its involvement also in the pathogenesis of typical HUS [13], thus supporting the “off label” use of an anti-C5-convertase monoclonal antibody (Eculizumab) for treating more severe forms of this disease (mainly with neurological involvement) [14–17]. In this report, we describe two cases of young female patients (9 and 2-year-old), who developed a serious form of typical HUS complicated by severe CNS damage, successfully treated with Eculizumab. They were successively affected by a severely disabling peripheral neurological involvement requiring an intensive multidisciplinary neurorehabilitation program at hospital discharge.

## Case presentation

### Case 1

A previously healthy 9-years-old girl was admitted to the Pediatric Infectious Disease Unit (PIDU) with bloody

diarrhea and anemia. According to regional guidelines for bloody diarrhea [18], stool research for STEC was performed and the presence of *E. Coli* O111 with gene toxin “attaching and effacing” (*eae*) was detected. On day 3, due to the rapid decline of renal function tests (serum creatinine 0,94 mg/dL, azotemia 67 mg/dL) and platelet (PLT) count ( $130 \times 10^3/\mu\text{L}$ ) and rising of LDH (830 U/l), the patient was transferred to our Pediatric Nephrology Unit. The general conditions were poor and the laboratory parameters further worsened due to the onset of septic shock (serum creatinine 2.74 mg/dL; azotemia 125 mg/dL; WBC  $31.2 \times 10^3/\mu\text{L}$ ; Neutrophils 67.5%; PLT  $24 \times 10^3/\mu\text{L}$ ; LDH 1763 U/l; CRP 141 mg/dL). On day 5, a severe CNS involvement appeared with sudden onset of generalized paresthesia, tingling of the lower limbs, convergence of the eyes, and short but frequent absence seizures (< 1 min of duration). Despite a negative brain computed tomography (bCT) and therapy with benzodiazepines and phenobarbital, at day 6 the general conditions further worsened and a coma status arose (Glasgow Coma Score or GCS 8/15) with immediate transfer to the Pediatric Intensive Care Unit (PICU) and start of the mechanical ventilation.

The electroencephalography (EEG) revealed diffuse slow-wave activity with delta oscillations in frontal area, while brain magnetic resonance (bMR) showed diffuse ischemic lesions mainly in basal nuclei but also in the brainstem (pons, medulla oblongata). Due to severe neurological involvement, the patient received an off-label treatment with Eculizumab (300 mg i.v.) on day 6 and after a week (day 13). Moreover, despite massive i.v. fluid over-hydration and massive diuretic therapy, she became anuric and renal function tests further worsened (serum creatinine 3.3 mg/dL). For these reasons, renal replacement therapy (RRT) by veno-ven hemodiafiltration (HDF) was started at day 7 and repeated every day until day 20. The improvement of blood pressure control was achieved with amlodipine and ramipril therapy. The general condition improved rapidly, thus on day 7 the patient was extubated and returned to our Nephrology Unit. Then, the patient developed a significant visual impairment with evidence of a papilla with blurred margins and hemorrhages along the superior temporal arch in the right eye and cotton exudates at the temporal side of the left eye. These findings were compatible with bilateral retinal vascular occlusion.

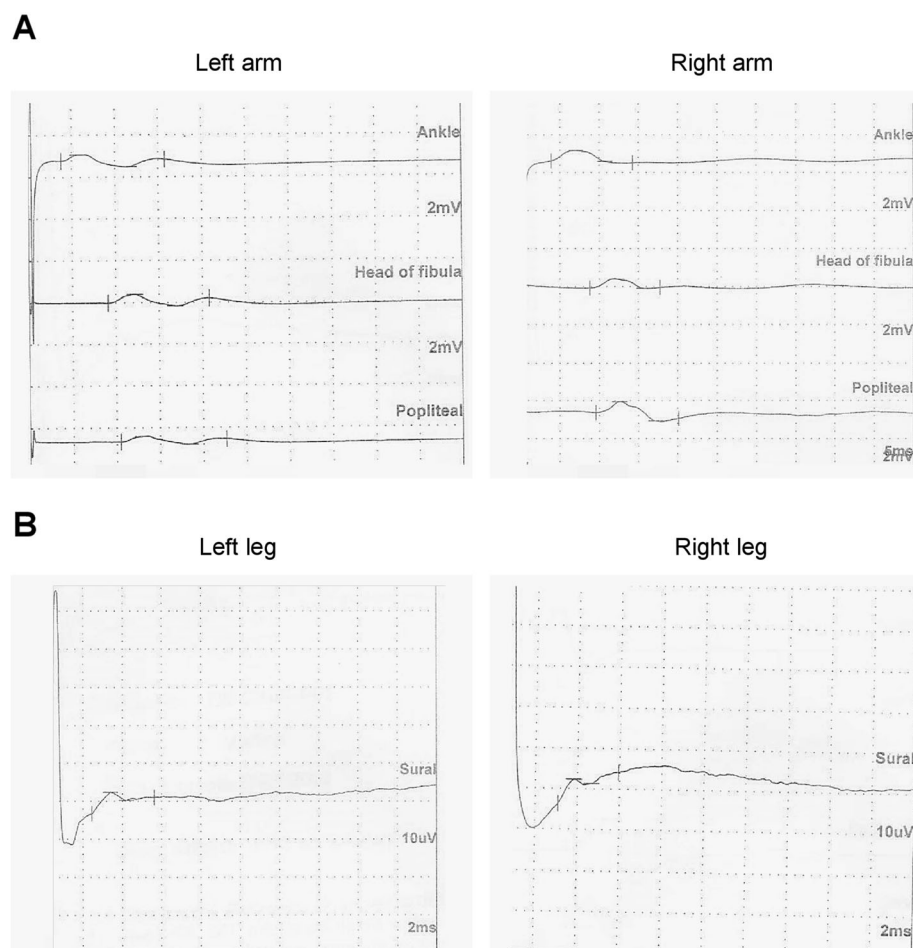
Progressively, general condition and diuresis improved, with normalization of laboratory parameters (at day 25: serum creatinine 0.89 mg/dL; azotemia 49 mg/dL; WBC  $7.53 \times 10^3/\mu\text{L}$ ; Neutrophils 50.1%; PLT  $330 \times 10^3/\mu\text{L}$ ; LDH 304 U/l; CRP 5 mg/dL), so RRT was stopped. Hypokalemia resulting from brisk diuresis was treated with intravenous potassium replacement until it normalized.

A further bMR revealed complete regression of the ischemic hypoxic areas at both the basal nuclei and the brainstem level. Also, EEG and visual impairment were normalized. On day 28, the onset of progressive intense bilateral lower limb pain with marked hyposthenia and inability to keep upright imposed further neurological evaluation. Both spinal cord MR and cerebrospinal fluid (CSF) analysis were normal. However, electroneurography (ENoG) of peripheral nerves revealed a low amplitude of compound motor action potentials (CMAP) in three sites at the peroneal motor nerve and a reduction of sensory action potential (SAP) at sural sensory nerve bilaterally, thus leading to a diagnosis of inflammatory polyneuropathy (Fig. 1A-B). Thus, combined therapy with methylprednisolone pulses (10 mg/kg  $\times$  3 days) and immunoglobulins (400 mg/kg/day for 4 days), followed by a motor-rehabilitation training program, gained a slight and progressive improvement of lower limbs pain and hyposthenia in the child. After 45 days, the patient was

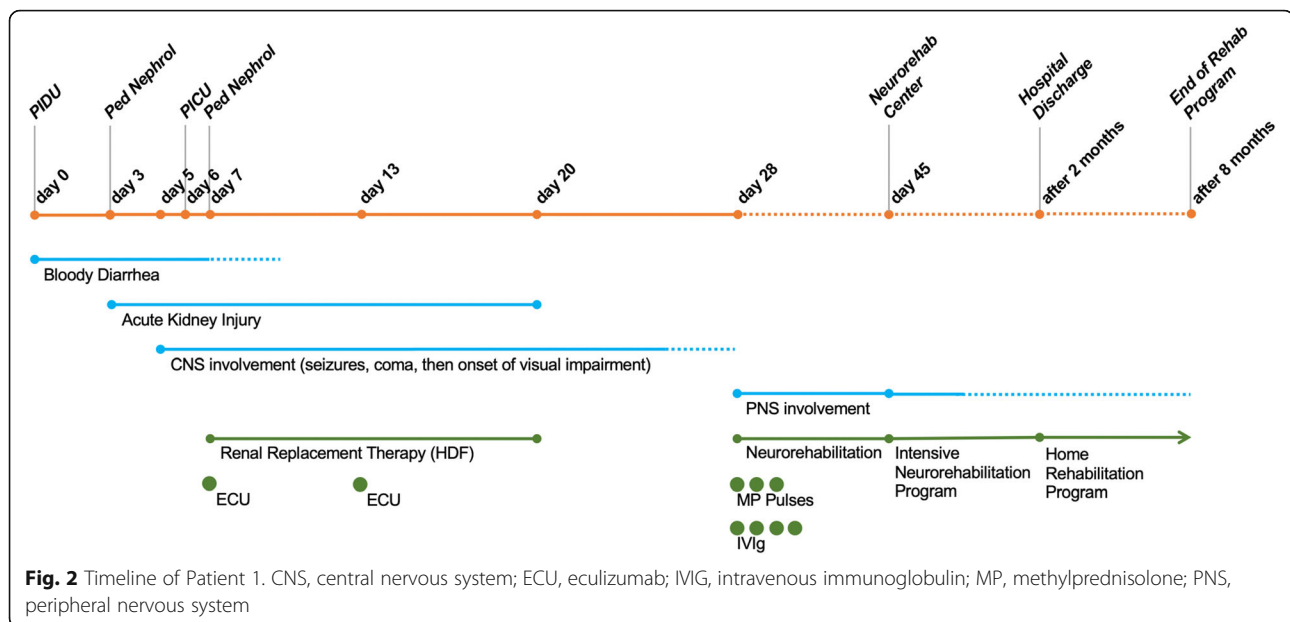
transferred to a neurorehabilitation center for further intensive treatment. The main clinical and therapeutic information about this case is reported as a timeline in Fig. 2.

### Case 2

A 2-years-old healthy girl was admitted to PIDU because of bloody diarrhea. Laboratory analysis showed neutrophilic leukocytosis (WBC  $13,83 \times 10^3/\mu\text{L}$ , Neutrophils 67%) while other parameters were normal (Haemoglobin or HGB 13,2 g/dl, PLT  $386 \times 10^3/\mu\text{L}$ , serum creatinine 0,29 mg/dl, CRP 4,8 mg/L). Fecal testing revealed enterohemorrhagic *E. coli* (STEC O111) with verocytotoxins *Stx2* and *eae*. Despite i.v. overhydration and massive diuretic therapy, she developed clinical signs of HUS with anemia, thrombocytopenia ( $38 \times 10^3/\mu\text{L}$ ), and renal function impairment (serum creatinine 2.28 mg/dl) with worsening of general conditions and, successively, oligoanuria. For these reasons, a session of renal replacement therapy (RRT) by HDF was started. During the first



**Fig. 1** Electroneurography of peripheral nerves revealing severe polyneuropathy. Low amplitude of the compound motor action potentials (CMAP) in three sites at the peroneal motor nerves (A) and reduction of sensory action potential (SAP) at sural sensory nerves, assessed bilaterally by electroneurography (ENoG) of peripheral nerves in patient 1



HDF session, the patient showed cardiovascular instability with the onset of neurological signs (strabismus and facial stereotypies). RRT session was suddenly stopped to perform a brain CT scan, resulted normal and then, because of worsening of metabolic acidosis (pH 7.18,  $\text{HCO}_3^-$  11.8 mmol/L, BE -15), the child was moved to PICU. At admission, she showed a coma status (GCS 8/15) and required starting of mechanical ventilation. The neurological assessment revealed normal pupillary reflexes without nuchal rigidity, while EEG revealed diffuse slow-wave activity with theta-delta oscillations of low voltage.

On day 3, due to a condition of severe hyperkalemia resistant to medical therapy (i.v. calcium gluconate, i.v. sodium bicarbonate, i.v. insulin, rectal sodium polystyrene sulfonate), the patient developed life-threatening bradycardia and underwent CPR. Urgently continuous veno-ven HF was performed over three consecutive days, then it was stopped and replaced by intermittent HDF until day 14. The onset of clinical and laboratory sign of multiorgan failure coupled to rhabdomyolysis required three sessions of CytoSorb® hemoadsorption (Cytosorbents Corporation, Monmouth Junction, NJ, USA) on day 6, 8 and 10 [19, 20].

On day 4, a brain MRI was performed, showing diffuse homogeneous signal hyperintensity in T2 and FLAIR sequences, with evident signal restriction in DWI and homogeneous hypointensity in T1-weighted sequences, localized in the deep posterior-lateral cortical area of both cerebellar hemispheres. These findings were compatible with severe post-anoxic damage, thus the patient received two doses of Eculizumab (300 mg i.v.) on day 4 and 11.

The patient remained in PICU for 14 days and was also treated with the best supportive therapy, including also i.v. antibiotics to treat a septic condition (culture-positive bronchial washing for *S. Marcescens*).

The general condition progressively improved and laboratory parameters gained almost normal values within 18 days. A further bMR imaging, on day 27, revealed a significant improvement of the ischemic hypoxic area at cerebellar level, confirmed by normal electrical activity at EEG monitoring.

After extubating, the neurological assessment revealed marked bilateral motor deficit with hyporeflexia/areflexia in the lower limbs and hyperextension of the thigh, while the upper limbs presented intentional tremors and normal reflexes. Moreover, the child also exhibited head postural tremors.

The patient returned to our Nephrology Unit on day 16. At admission, the diuresis was adequate and the renal function was recovered (serum creatinine 1.06 mg/dL). Hypokalemia resulting from brisk diuresis was treated with intravenous potassium replacement until it normalized, while blood pressure control was improved with amlodipine and ramipril.

Due to the persistent severe bilateral motor deficit with hyporeflexia/areflexia in the lower limbs and intentional tremors of both the upper limbs, a deep neurological reassessment with ENoG revealed severe axonal damage with both motor and sensory demyelination of the lower limbs, mainly at right. The peripheral polyneuropathy was treated with therapeutic plasma exchange (TPE) (seven treatments), but the functional recovery was unsatisfactory, because of the persisting of lower limb asthenia and bilateral absence of

osteotendinous reflexes. Thus, on day 35 the patient was discharged and was transferred to a neuro-rehabilitation center for intensive treatment. Main clinical and therapeutic information about this case is reported as a timeline in Fig. 3.

**Neuro-rehabilitation program**

Before starting the treatment, neurological examination and psychiatric functional evaluation in both patients revealed an inability to walk and symmetrical hypotonia, with lower limbs weaker than upper limbs, lying in a frog-like position, deep tendon reflexes decreased in all extremities. No Babinski’s bilateral signs were present. Furthermore, patient 1 showed distal lower limbs mild hypotrophy and scoliosis, while patient 2 clinical presentation was more severe, with bilateral ankle contractures. The neuropsychological profile was within normal limits in both patients.

In patient 1, visual evoked potential showed both the reductions in P100 amplitude and increments in P100 latency at the right occipital area, while no specific abnormalities have been revealed on the left. The latter was normal in patient 2, who instead presented retinal dystrophy in the right eye and scotopic and photopic full-field ERG characterized by reduced amplitudes particularly in scotopic condition; the left eye was normal.

In these cases, physiotherapy and occupational therapy were started including specific therapeutic activities; during the first stage, when the voluntary movement was compromised, passive kinesitherapy has been initiated to

improve local blood circulation and to avoid joint stiffness, tendon retractions, and muscle contractures due to protracted immobility.

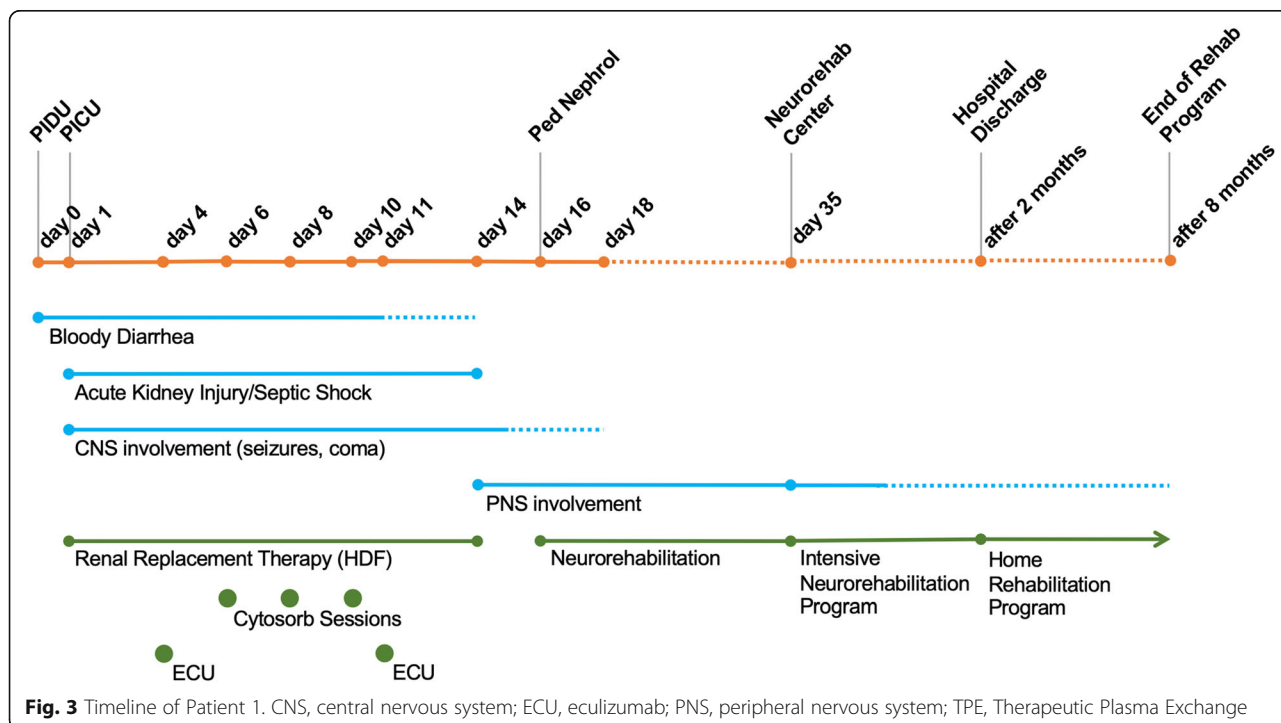
After the appearance of voluntary activity event, active kinesitherapy has been progressively introduced through a gentle submaximal and aerobic functional exercise, that was carried out with adequate monitoring, with pauses according to the needs of the patient and with graduated assistance [21].

In patient 2, ankle foot orthoses (AFOs) was also used to minimize contractures and to improve both the stance and swing phases of gait.

Moreover, the neuro-rehabilitation program included exercises to improve coordination and balance. Our patients received this specific and intensive physiotherapy program and, after a 2 months term, they developed a progressive improvement on muscular strength and on motor functions.

We have used the Functional Independence Measure for Children (WeeFIM) [22] to assess outcomes from neuro-rehabilitation and significant changes have been found in both patients particularly concerning to the motor scale (Table 1).

In both patients, neurological examination revealed the recovery of autonomous deambulation and improvement in postural changes, but the walk was still unstable, with a wide base and the feet thrown out, and the equilibrium was mildly unstable. Besides, both children showed full adherence to the hospital-based neuro-rehabilitation program without significant adverse



**Fig. 3** Timeline of Patient 1. CNS, central nervous system; ECU, eculizumab; PNS, peripheral nervous system; TPE, Therapeutic Plasma Exchange



**Table 1** Overview of the Functional Independence Measure (FIM) for children at admission and discharge

Case 1			Case 2		
Item (scale)	Admission	Discharge	Item (scale)	Admission	Discharge
FIM motor	2.08	4.62	FIM motor	1.23	1.69
FIM cognitive	3.22	5.11	FIM cognitive	2.6	2.6
FIM total	58	92	FIM total	29	35

events, and they continued a home-based rehabilitation once discharged. After further 8 months of home rehabilitation, both patients were re-evaluated with evidence of complete functional recovery.

### Genetic screening

Both the patients were clearly affected by a STEC-HUS related to *E. Coli* O111 infection. However, due to very severe neurological impairment, genetic screening of all exons and flanking regions of CFH, CD46, CFI, CFB, C3, THBD, DGKE, C5, CFHR1–5, MMACHC and ADAMTS13 was performed through next-generation sequencing (NGS), as described elsewhere [23, 24], but no pathogenic variants were identified. Moreover, none of them presented genetic variants of C5 gene, which are related to low response to Eculizumab [25].

### Discussion and conclusion

Neurological involvement is the most frequent extrarenal manifestation during typical HUS, accounting for almost 17–34% of patients [7]. This complication significantly worsens patients' survival and may lead to severe permanent disability, since end stage renal disease requiring chronic hemodialysis and/or kidney transplantation following typical HUS-induced AKI accounts for only 3% of cases [26–28].

Typical HUS-mediated CNS injury may vary from mild to severe and potentially life-threatening manifestations, ranging from eye disorders (strabismus, nystagmus, visus disorders/amaurosis), to alterations of communication skills, to CNS disorders (hypo/hypertensive disorders of muscle tone, neuro-vegetative system disorders, alteration of consciousness, epileptic seizures until coma) [7].

Among neurological assessment techniques, brain MR is actually the gold standard method to analyze brain damage location and extent during typical HUS, which mainly, but not only, involves basal nuclei with a pattern in early diffusion-weighted T1 sequence. However, given the wide clinical spectrum of neurological signs, lesions at different levels of CNS have also been reported [29]. Based on both MR findings and the location of the lesions, the main pathogenic mechanism seems to be ischemic injury after thrombotic microangiopathy onset with rising evidence of complement system involvement [9]. Although controlled clinical trials are lacking, all

these findings strongly suggest a key role of early administration of Eculizumab, and anti-C5 convertase monoclonal antibody, to halt and potentially reverse the TMA-mediated severe neurological involvement, as well as at renal levels. Rising evidence support the efficacy and safety of Eculizumab administration to treat the severe neurologic involvement in typical HUS patients [30, 31]. Indeed, even in our cases, the central nervous system damage following typical HUS onset was effectively reverted by early Eculizumab administration.

Although several works describe a wide spectrum of clinical and radiological signs affecting CNS during typical HUS, very little is reported about peripheral nerve involvement. In a single report, the authors described the case of a pediatric patient with severe STEC-HUS belatedly complicated by a disabling peripheral neuropathy, as in our two cases [12].

Neurological emergencies are frequent in patients with hematological disorders, for instance during thrombotic microangiopathies, which involves both the central and peripheral nervous system [32]. In limited cases, when nerve biopsy was available, thrombosis of epineurial blood vessels with inflammation was shown, thus demonstrating that thrombotic microangiopathy can involve the peripheral nerves, resulting in major morbidity [33]. In this report, we described two cases of severe PNS involvement following typical HUS and underline the efficacy of a prompt neuro-rehabilitation program, coupled with adequate supportive care. The pathogenic mechanism of peripheral nerve involvement during typical HUS is unknown. In experimental models, the evidence of verotoxin receptors in peripheral nerves strongly suggests a possible direct neuropathic effect of STEC infection [34]. However, in our two cases, the lack of nerve biopsy does not allow us to draw definitive conclusions about the pathogenesis of the typical HUS-related peripheral neuropathy. Intriguingly in both cases, the late onset of PNS involvement after resolution of CNS injury seems to suggest a possible role for dystrophic phenomena affecting the peripheral nerves, probably due to typical HUS-related lack of nutrients (i.e. probiotics or vitamins) [35], which in other clinical settings may lead to peripheral neuropathy [36, 37]. Generally, we can consider the peripheral nerve as a complex system in which the endoneurial homeostasis is strictly regulated via tight junction-forming endoneurial microvessels that

control ion, solute, water, nutrient, macromolecule, and leukocyte influx and efflux between the bloodstream and endoneurium; thus, it is not daring to speculate that the STEC-related blood stream disorders (i.e. leukocytosis, electrolyte alterations, toxin trafficking) may affect the blood-nerve barrier integrity and function, thus leading to more or less severe decay of the peripheral nervous system [38].

A correct diagnostic evaluation could help us to differentiate several types of muscular disorders, although the temporal sequence of clinical events suggests a close correlation between HUS and PNS manifestations [39]. Furthermore, pediatric neuromuscular diseases involving PNS are mainly due to genetic etiology, and therefore they can easily be ruled out in our cases which have occurred as a result of an acute illness [40].

Although immunotherapies with monoclonal antibodies may induce peripheral neuropathic side effects and, rarely, immune axonal acquired neuropathies [41], this complication seems unlikely after Eculizumab infusion and up to now no cases have been described. Moreover, in the second case here reported, the severe peripheral neuropathy could be immune-mediated, thus suggesting a rescue therapy with plasma-exchange (PE). Unlike rehabilitation therapy, this approach did not gain any benefit and has been halted after 6 sessions. The absent response to TPE further excludes the hypothesis of an immune-mediated peripheral neurological damage in our cases.

In conclusion, peripheral nerve involvement during typical HUS is a very rare, but potentially severely invalidating event. Although we described just two cases of severe PNS involvement following typical HUS infection, the early treatment of this complication with prompt neuro-rehabilitation, coupled with adequate supportive care, is essential to prevent permanent and irreversible damage and may significantly improve the clinical outcome of these pediatric patients.

#### Abbreviations

AFO: Ankle Foot Orthoses; aHUS: atypical Hemolytic uremic syndrome; BE: Base Excess; CFE: Cerebrospinal fluid examination; CMAP: Compound Motor Action Potentials; CNS: Central nervous system; CPR: Cardiopulmonary resuscitation; CRP: C-reactive protein; CT: Computer Tomography; EEG: Electroencephalography; EHEC: Entero-Hemorrhagic *Escherichia Coli*; EMG: Electromyography; ENoG: Electroneurography; ERG: Electroretinography; FIM: Functional Independence Measure; GCS: Glasgow Coma Score; HCO<sup>3-</sup>: Bicarbonate Ion; HDF: Hemodialfiltration; HGB: Haemoglobin; HUS: Hemolytic uremic syndrome; IV: Intra-venous (therapy); LDH: Lactate dehydrogenase; MR: Magnetic resonance; Neut: Neutrophils; PICU: Pediatric intensive care unit; PLT: Platelets (count); PNS: Peripheral nervous system; RRT: Renal replacement therapy; SAP: Sensory Action Potential; sCr: serum Creatinine; STEC: Shiga-like toxin-producing *E. coli*; TMA: Thrombotic Micro-Angiopathy; TPE: Therapeutic Plasma Exchange; WBC: White blood cell (count)

#### Acknowledgements

The authors thank Mrs. Mariella Ragone, the nurse coordinator, and Dr. Antonio Ranieri and Vito Bellino, Dialysis Technician at the Pediatric

Nephrology Unit of the Pediatric Hospital "Giovanni XXIII", Bari (Italy), for their invaluable collaboration.

#### Authors' contributions

Luisa Santangelo conceived and designed the study, analyzed the data and drafted the manuscript; Giuseppe Stefano Netti analyzed the data, interpreted results and prepared the figures; Diletta D. Torres, Giovanni Piscopo, Vincenza Carbone, Luciana Losito, Leonardo Milella, Maria Luigia Lasorella, Pasquale Conti and Delio Gagliardi collected the clinical data and helped to interpret the results; Maria Chironna, Federica Spadaccino, Elena Bresin and Antonio Trabacca, helped to draft the manuscript; Elena Ranieri and Mario Giordano edited and revised manuscript and approved the final version of manuscript. The authors read and approved the final manuscript.

#### Funding

The present work was funded by University Research Projects 2019 (PRA 2019) granted by University of Foggia to Giuseppe Stefano Netti.

#### Availability of data and materials

The datasets used and/or analysed during the current study are available from the corresponding author on reasonable request.

#### Declarations

##### Ethics approval and consent to participate

The present study has carried out retrospectively based on registry data. All procedures performed were in accordance with the 1964 Helsinki declaration and its later amendments. Ethical approval has been obtained from the Institutional Review Board of the University Hospital "Policlinico Consorziale" of Bari (Italy) (Prot. 1624/2018).

##### Consent for publication

The authors declare their consent to publication this manuscript in the present form.

All the minors' legal guardians signed a written informed consent to collect their clinical data at time of hospital access and for the publication of any potentially identifiable images or data included in this article.

##### Competing interests

The authors declare that they have no competing interests.

##### Author details

<sup>1</sup>Pediatric Nephrology and Dialysis Unit, Pediatric Hospital "Giovanni XXIII", Bari, Italy. <sup>2</sup>Department of Medical and Surgical Sciences, Clinical Pathology Unit and Center for Molecular Medicine, University of Foggia, Viale Luigi Pinto -, 71122 Foggia, Italy. <sup>3</sup>Scientific Institute I.R.C.C.S. "E. Medea"- Unit for Severe disabilities in developmental age and young adults (Developmental Neurology and Neurorehabilitation), Brindisi, Italy. <sup>4</sup>Intensive Care Unit, Pediatric Hospital "Giovanni XXIII", Bari, Italy. <sup>5</sup>Pediatric Neurology Unit, Pediatric Hospital "Giovanni XXIII", Bari, Italy. <sup>6</sup>Department of Biomedical Sciences and Human Oncology, Hygiene Unit, University of Bari "Aldo Moro", Bari, Italy. <sup>7</sup>Clinical Research Center for Rare Diseases "Aldo e Cele Daccò", Istituto di Ricerche Farmacologiche Mario Negri IRCCS, Bergamo, Italy.

Received: 14 February 2021 Accepted: 16 August 2021

Published online: 06 September 2021

#### References

- Mele C, Remuzzi G, Noris M. Hemolytic uremic syndrome. *Semin Immunopathol.* 2014;36(4):399–420. <https://doi.org/10.1007/s00281-014-0416-x>.
- Geerdink LM, Westra D, van Wijk JA, Dorresteijn EM, Lilien MR, Davin JC, et al. Atypical hemolytic uremic syndrome in children: complement mutations and clinical characteristics. *Pediatr Nephrol.* 2012;27:1283–91. <https://doi.org/10.1007/s00467-012-2131-y>.
- Noris M, Caprioli J, Bresin E, Mossali C, Pianetti G, Gamba S, et al. Relative role of genetic complement abnormalities in sporadic and familial aHUS and their impact on clinical phenotype. *Clin J Am Soc Nephrol.* 2010;5(10):1844–59. <https://doi.org/10.2215/CJN.02210310>.
- Fremaux-Bacchi V, Fakhouri F, Garnier A, Bienaime F, Dragon-Durey MA, et al. Genetics and outcome of atypical hemolytic uremic syndrome: a

- nationwide French series comparing children and adults. *Clin J Am Soc Nephrol*. 2013;8(4):554–62. <https://doi.org/10.2215/CJN.04760512>.
5. Jokiranta TS. HUS and atypical HUS. *Blood*. 2017;129(21):2847–56. <https://doi.org/10.1182/blood-2016-11-709865>.
  6. Loirat C, Fakhouri F, Ariceta G, Besbas N, Bitzan M, Bjerre A, et al. An international consensus approach to the management of atypical hemolytic uremic syndrome in children. *Pediatr Nephrol*. 2016;31(1):15–39. <https://doi.org/10.1007/s00467-015-3076-8>.
  7. Khalid M, Andreoli S. Extrarenal manifestations of the hemolytic uremic syndrome associated with Shiga toxin-producing *Escherichia coli* (STEC HUS). *Pediatr Nephrol*. 2019;34(12):2495–507. <https://doi.org/10.1007/s00467-018-4105-1>.
  8. Matthies J, Hünseler C, Ehren R, Volland R, Körber F, Hoppe B, et al. Extrarenal manifestations in Shiga toxin-associated Haemolytic uremic syndrome. *Klin Paediatr*. 2016;228(4):181–8. <https://doi.org/10.1055/s-0042-108444>.
  9. Trachtman H, Austin C, Lewinski M, Stahl RA. Renal and neurological involvement in typical Shiga toxin-associated HUS. *Nat Rev Nephrol*. 2012; 8(11):658–69. <https://doi.org/10.1038/nrneph.2012.196>.
  10. Otukesh H, Hoseini R, Golnari P, Fereshtehnejad SM, Zamanfar D, Hooman N, et al. Short-term and long-term outcome of hemolytic uremic syndrome in Iranian children. *J Nephrol*. 2008;21(5):694–703. PMID: 18949724.
  11. Santangelo L, Netti GS, Giordano P, Carbone V, Martino M, Torres DD, et al. Indications and results of renal biopsy in children: a 36-year experience. *World J Pediatr*. 2018;14(2):127–33. <https://doi.org/10.1007/s12519-018-0147-5>.
  12. Adamczuk D, Ziolkowska H, Leszczyńska B, Roszkowska-Blaim M. Ciezki przebieg typowego zespołu hemolityczno-mocznicowego u 14-letniego chłopca [Severe course of typical hemolytic-uremic syndrome in a 14-year-old boy]. *Pol Merkuriusz Lekarski*. 2009;26(154):340–2. PMID: 19580203.
  13. Thurman JM, Marians R, Emlen W, Wood S, Smith C, Akana H, et al. Alternative pathway of complement in children with diarrhea-associated hemolytic uremic syndrome. *Clin J Am Soc Nephrol*. 2009;4(12):1920–4. <https://doi.org/10.2215/CJN.02730409>.
  14. Lapeyraque AL, Malina M, Fremaux-Bacchi V, Boppel T, Kirschfink M, Oualha M, et al. Eculizumab in severe Shiga-toxin-associated HUS. *N Engl J Med*. 2011;364(26):2561–3. <https://doi.org/10.1056/NEJMcl100859>.
  15. Giordano P, Netti GS, Santangelo L, Castellano G, Carbone V, Torres DD, et al. A pediatric neurologic assessment score may drive the eculizumab-based treatment of *Escherichia coli*-related hemolytic uremic syndrome with neurological involvement. *Pediatr Nephrol*. 2019;34(3):517–27. <https://doi.org/10.1007/s00467-018-4112-2>.
  16. Netti GS, Santangelo L, Paulucci L, Piscopo G, Torres DD, Carbone V, et al. Low C3 serum levels predict severe forms of STEC-HUS with neurologic involvement. *Front Med*. 2020;7:357. <https://doi.org/10.3389/fmed.2020.00357>.
  17. Walsh PR, Johnson S. Eculizumab in the treatment of Shiga toxin haemolytic uremic syndrome. *Pediatr Nephrol*. 2019;34(9):1485–92. <https://doi.org/10.1007/s00467-018-4025-0>.
  18. Loconsole D, Giordano M, Laforgia N, Torres DD, Santangelo L, Carbone V, et al. Case-management protocol for bloody diarrhea as a model to reduce the clinical impact of Shiga toxin-producing *Escherichia coli* infections. Experience from southern Italy. *Eur J Clin Microbiol Infect Dis*. 2019;39(3): 539–47. <https://doi.org/10.1007/s10096-019-03755-0>.
  19. Netti GS, Sangregorio F, Spadaccino F, Staffieri F, Crovace A, Infante B, et al. LPS removal reduces CD80-mediated albuminuria in critically ill patients with gram-negative sepsis. *Am J Physiol Ren Physiol*. 2019;316(4):F723–31. <https://doi.org/10.1152/ajprenal.00491.2018>.
  20. Castellano G, Stasi A, Franzin R, Sallustio F, Divella C, Spinelli A, et al. LPS-binding protein modulates acute renal fibrosis by inducing Pericyte-to-Myofibroblast trans-differentiation through TLR-4 signaling. *Int J Mol Sci*. 2019;20(15):3682. <https://doi.org/10.3390/ijms20153682>.
  21. Casale R, La Manna A, Salvini S, Maini M, Ceccherelli F, Frazzitta G. Peripheral neuropathy rehabilitation. Indications for a diagnostic-rehabilitation approach. *G Ital Med Lav Ergon*. 2003;25(4):456–64. PMID: 15027694.
  22. Ottenbacher KJ, Msall ME, Lyon N, Duffy LC, Ziviani J, CGranger CV, et al. The WeeFIM instrument: its utility in detecting change in children with developmental disabilities. *Arch Phys Med Rehabil*. 2000;81(10):1317–26. <https://doi.org/10.1053/apmr.2000.9387>.
  23. Valoti E, Alberti M, Iatropoulos P, Piras R, Mele C, Breno M, et al. Rare functional variants in complement genes and anti-FH autoantibodies-associated aHUS. *Front Immunol*. 2019;10:853. <https://doi.org/10.3389/fimmu.2019.00853>.
  24. de Martino M, Gigante M, Cormio L, Praticchizzo C, Cavalcanti E, Gigante M, et al. JAK3 in clear cell renal cell carcinoma: mutational screening and clinical implications. *Urol Oncol*. 2013;31(6):930–7. <https://doi.org/10.1016/j.urolonc.2011.07.001>.
  25. Nishimura J, Yamamoto M, Hayashi S, Ohyashiki K, Ando K, Brodsky AL, et al. Genetic variants in C5 and poor response to eculizumab. *N Engl J Med*. 2014;370(7):632–9. <https://doi.org/10.1056/NEJMoa1311084>.
  26. Spinale JM, Ruebner RL, Copelovitch L, Kaplan BS. Long-term outcomes of Shiga toxin hemolytic uremic syndrome. *Pediatr Nephrol*. 2013;28(11): 20972105. <https://doi.org/10.1007/s00467-012-2383-6>.
  27. Santangelo L, Gigante M, Netti GS, Diella S, Puteo F, Carbone V, et al. A novel SMARCAL1 mutation associated with a mild phenotype of Schimke immuno-osseous dysplasia (SIOD). *BMC Nephrol*. 2014;15(1):41. <https://doi.org/10.1186/1471-2369-15-41>.
  28. Gigante M, d'Altilia M, Montemurno E, Diella S, Bruno F, Netti GS, et al. Branchio-Oto-renal syndrome (BOR) associated with focal glomerulosclerosis in a patient with a novel EYA1 splice site mutation. *BMC Nephrol*. 2013; 14(1):60. <https://doi.org/10.1186/1471-2369-14-60>.
  29. Löbel U, Eckert B, Simova O, Meier-Cillien S, Kluge S, Gerloff C, et al. Cerebral magnetic resonance imaging findings in adults with haemolytic uraemic syndrome following an infection with *Escherichia coli*, subtype O104:H4. *Clin Neuroradiol*. 2014;24(2):111–9. <https://doi.org/10.1007/s00062-013-0231-0>.
  30. Pape L, Hartmann H, Bange FC, Suerbaum S, Bueltmann E, Ahlenstiel-Grunow T. Eculizumab in Typical Hemolytic Uremic Syndrome (HUS) With Neurological Involvement. *Medicine*. 2015;94:e1000. <https://doi.org/10.1097/MD.0000000000001000>.
  31. Percheron L, Gramada R, Tellier S, Salomon R, Harambat J, Llanas B, et al. Eculizumab treatment in severe pediatric STEC-HUS: a multicenter retrospective study. *Pediatr Nephrol*. 2018;33(8):1385–94. <https://doi.org/10.1007/s00467-018-3903-9>.
  32. Cruz ML, Farooq S, Testai FD. Neurological and neurosurgical emergencies in patients with hematological disorders. *Curr Neurol Neurosci Rep*. 2017; 17(3):24. <https://doi.org/10.1007/s11910-017-0728-z>.
  33. Naddaf E, James B, Dyck P, Said S, Amer H. Thrombotic microangiopathy involving kidney allograft and peripheral nerves. *Am J Transplant*. 2020; 20(5):1454–6. <https://doi.org/10.1111/ajt.15736>.
  34. Ren J, Utsunomiya I, Taguchi K, Ariga T, Tai T, Ihara Y, et al. Localization of verotoxin receptors in nervous system. *Brain Res*. 1999;825(1–2):183188. [https://doi.org/10.1016/S0006-8993\(99\)01196-8](https://doi.org/10.1016/S0006-8993(99)01196-8).
  35. Giordano M, Baldassarre ME, Palmieri V, Torres DD, Carbone V, Santangelo L, et al. Management of STEC gastroenteritis: is there a role for probiotics? *Int J Environ Res Public Health*. 2019;16(9):1649. <https://doi.org/10.3390/ijerph16091649>.
  36. Nadjar Y, Souvannanorath S, Maisonobe T, Brisset M, De Lonlay P, Schiff M, et al. Sensory neuropathy as a major clinical feature of mitochondrial trifunctional protein deficiency in adults. *Rev Neurol (Paris)*. 2020;176(5):380–6. <https://doi.org/10.1016/j.neuro.2019.11.011>.
  37. Morel L, Domingues O, Zimmer J, Michel T. Revisiting the role of neurotrophic factors in inflammation. *Cells*. 2020;9(4):E865. <https://doi.org/10.3390/cells9040865>.
  38. Ubogu EE. Biology of the human blood-nerve barrier in health and disease. *Exp Neurol*. 2020;328:113272. <https://doi.org/10.1016/j.expneurol.2020.113272>.
  39. Falsaperla R, Praticò AD, Ruggieri M, Parano E, Rizzo R, Corsello G, et al. Congenital muscular dystrophy: from muscle to brain. *Ital J Pediatr*. 2016; 42(1):78. <https://doi.org/10.1186/s13052-016-0289-9>.
  40. Dowling JJ, D Gonorazky H, Cohn RD, Campbell C. Treating pediatric neuromuscular disorders: the future is now. *Am J Med Genet A*. 2018;176(4): 804–41. <https://doi.org/10.1002/ajmg.a.38418>.
  41. Davies AJ, Rinaldi S, Costigan M, Oh SB. Cytotoxic immunity in peripheral nerve injury and pain. *Front Neurosci*. 2020;14:142. <https://doi.org/10.3389/fnins.2020.00142>.

## Publisher's Note

Springer Nature remains neutral with regard to jurisdictional claims in published maps and institutional affiliations.